

EP CASE REPORT

Peritoneal pericardial fistula post epicardial ventricular tachycardia ablation

Sharon Shalom Natanzon*, Roy Beinart, and Eyal Nof

Davidai Arrhythmia Center, Leviev Heart Center, Sheba Medical Center, Tel Hashomer and The Sackler Faculty of Medicine, Tel Aviv University, Tel Aviv, Israel

* Corresponding author. Tel: 00972522586251; fax: 0097235302171. E-mail address: sharonnatanzon@gmail.com

Ventricular tachycardia ablation is being commonly used today by electrophysiologist,¹ however VT ablation, specifically epicardial ablation is not without complications.^{2,3}

A 69-year-old male patient with recurrent sustained monomorphic ventricular tachycardia (VT) was referred to our institute for a radiofrequency ablation procedure. He presented with a history of paroxysmal atrial fibrillation, ischaemic heart disease, s/p anterior myocardial infarction (1994), and hospitalizations due to congestive heart failure exacerbations.

Surface ECG revealed slow monomorphic VT with mild haemodynamic compromise. The VT morphology consisted of slurred wide QRS complexes with right bundle branch block, right axis, and basal lateral exit at 110 b.p.m. He was treated with amiodarone, anti-tachycardia pacing, and electrical cardioversion which restored sinus rhythm. A few days later the same VT occurred and converted to sinus only after lidocaine infusion. The patient was scheduled for VT ablation with extracorporeal membrane oxygenation (ECMO) support. Due to the slurred R wave morphology of the VT, it was decided to perform an epicardial and endocardial approach.

A Touhey needle was advanced under fluoroscopy via the left lateral position with dye injection guidance. After dye injection confirmed that the tip of the needle was in the epicardial space, a long wire was advanced into the epicardium via the left anterior oblique position. Attempts to advance a long 7-Fr dilator on the wire into the pericardial space failed. Three taps were performed until a dilator could be advanced, then a 7-Fr arrow 21 CN sheath was advanced as pre-dilatation and eventually a short Agilis sheath was inserted.

All inducible sustained monomorphic VTs were targeted for ablation. Furthermore, scar substrate modification ('scar de-channelling') was performed.

Epicardial mapping identified a large anterior area of low voltage, albeit without areas of late potentials (LP) or areas of long S-QRS. Endocardial mapping revealed a large anterior septal scar. Areas with LP or long S-QRS were tagged. Program stimulation (PS) with a basic drive train of 600 and 2 extra stimuli (ES) induced a VT of different morphology (left bundle branch block in V1, left axis, and apical septal exit). This VT was unstable even with maximal ECMO support but terminated after several minutes.

All tagged areas were ablated till electrical inexcitability was achieved. Following this, the patient remained non-inducible with a PS of 500 and 3 ES. A pericardial drainage tube was inserted and attached to a vacuum bottle.

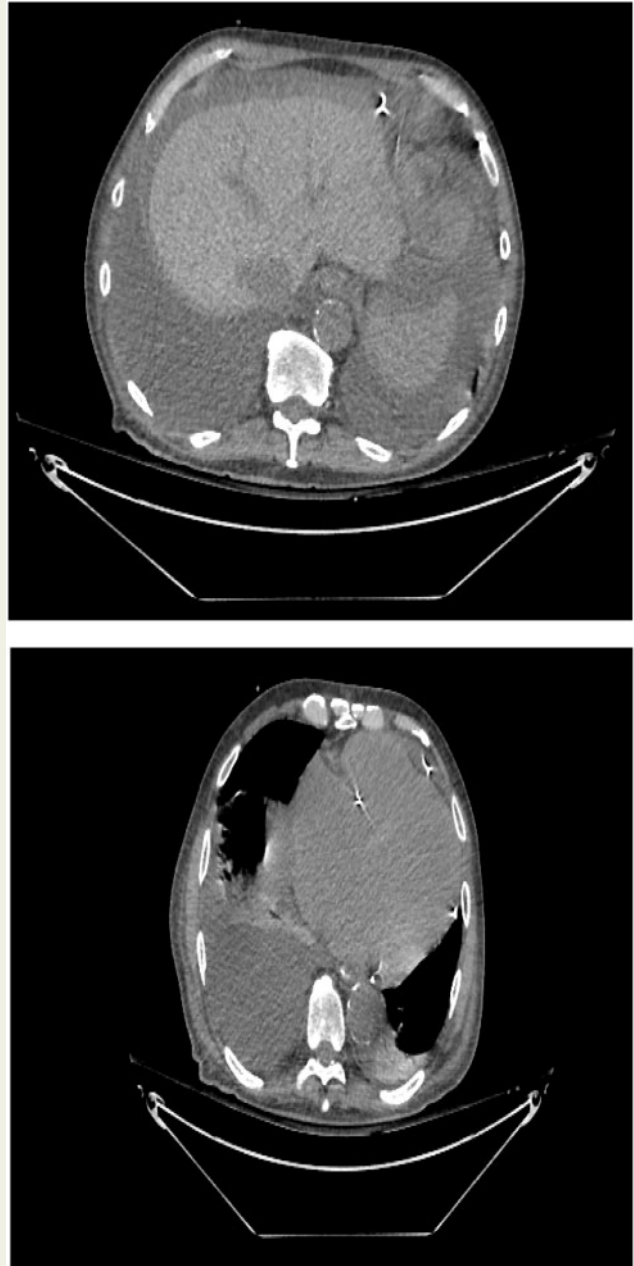


Figure 1 Pericardial tube traversing abdominal cavity. Large ascites fluid is also present (*upper panel*). Pericardial tube in pericardial sac. Large pleural fluid is also present (*lower panel*).

During the first 4 h following the procedure the pericardial drain continuously drained 3 L of serotic fluid. Echocardiography was performed, but pericardial fluid was not seen. The patient remained haemodynamically stable and even reported improvement in his heart failure symptoms. Fluid haemoglobin count was 0.8 g/L excluding haemopericardium. Chest and abdominal computed tomography confirmed that the drain was in the pericardial space ([Figure, lower panel](#)). Computed tomography also showed a large amount of fluid in the abdomen ([Figure, upper panel](#)). Interestingly, closing the vacuum for an hour did not result in epicardial fluid accumulation.

Our diagnosis was that when opened to vacuum, the drain resulted in negative pressure in the pericardial space. This pressure resulted in passage of the ascites to the pericardial space via a fistula caused by the initial pericardial taps.

Conflict of interest: none declared.

References

1. Al-Khatib SM, Stevenson WG, Ackerman MJ, Bryant WJ, Callans DJ, Curtis AB *et al.* 2017 AHA/ACC/HRS Guideline for management of patients with ventricular arrhythmias and the prevention of sudden cardiac death: executive summary: a report of the American College of Cardiology/American Heart Association Task Force on Clinical Practice Guidelines and the Heart Rhythm Society. *Heart Rhythm* 2018;**15**:e190–252.
2. Tung R, Michowitz Y, Yu R, Mathuria N, Vaseghi M, Buch E *et al.* Epicardial ablation of ventricular tachycardia: an institutional experience of safety and efficacy. *Heart Rhythm* 2013;**10**:490–8.
3. Bella PD, Brugada J, Zeppenfeld K, Merino J, Neuzil P, Maury P *et al.* Epicardial ablation for ventricular tachycardia: a European Multicenter Study. *Circ Arrhythm Electrophysiol* 2011;**4**:653–9.